

# Quadrilateral Space Syndrome

Robert C. Manske, PT, DPT, MEd, SCS, ATC, CSCS, Afton Sumler, ATC, and Jodi Runge, ATC  
• Wichita State University

## KEY POINTS

▶ Quadrilateral space syndrome is an uncommon condition.

▶ Symptoms are caused by entrapment of the axillary nerve within the quadrilateral space.

▶ Conservative treatment should be attempted prior to surgical intervention.

QUADRILATERAL space syndrome (QSS) is a uncommon condition that has been reported to affect athletes who perform overhead movement patterns, such as baseball players,<sup>1-4</sup> tennis players,<sup>5</sup> and volleyball players.<sup>6</sup> Cahill and Palmer<sup>7</sup> described it as a rare condition that involves compression of the

posterior humeral circumflex artery (PHCA) and the axillary nerve within the quadrilateral space, which produces pain over the posterior aspect of the shoulder that may radiate into the arm and forearm with a non-dermatomal distribution. Symptoms typically occur with the arm in an over-

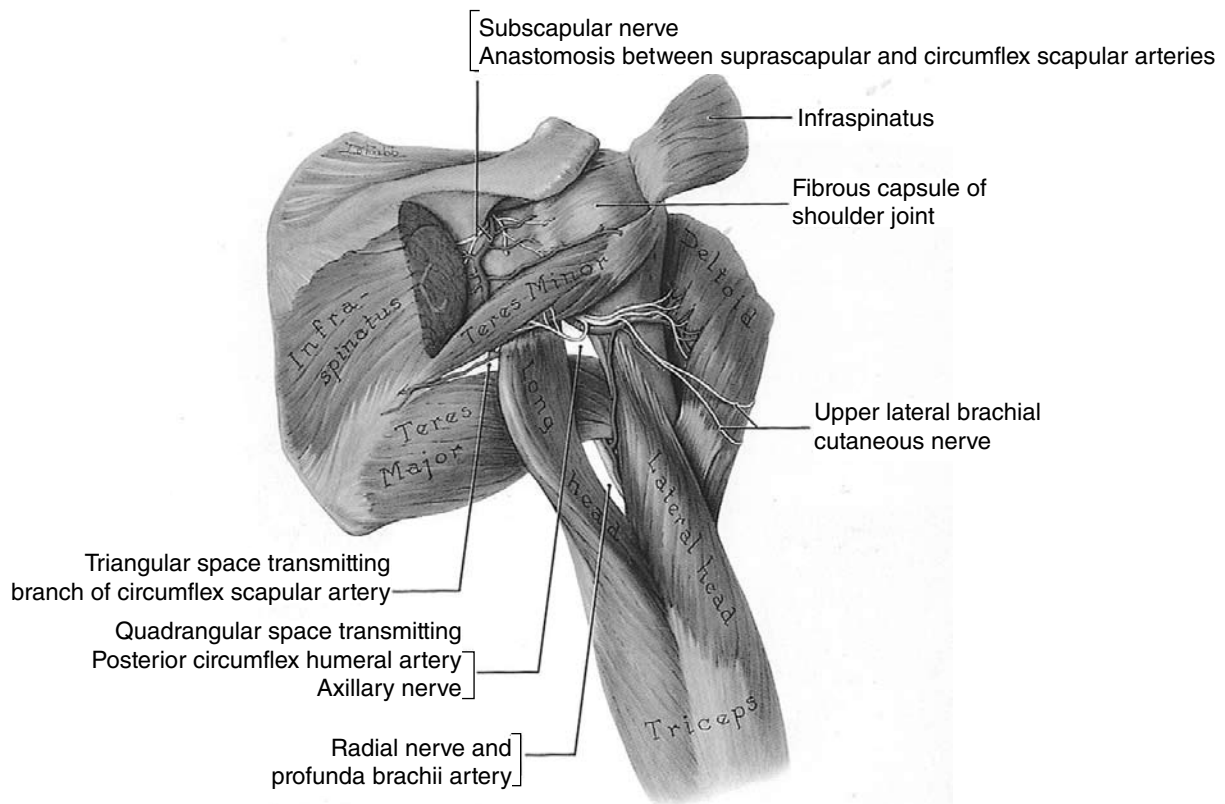
head position, e.g., the late cocking or early acceleration phase of the throwing motion. The quadrilateral space is formed by the teres major inferiorly, the long head of the triceps medially, the teres minor posteriorly, the subscapularis anteriorly, and the surgical neck of the humerus laterally (Figure 1).<sup>7</sup> This space is located in close proximity to the posterior band of the inferior joint capsule of the glenohumeral joint. It is not uncommon for athletes who perform overhead movement patterns to be positioned in abduction and extreme external rotation.

## History

QSS has been reported to have a spontaneous onset during sport participation or as a result of acute trauma.<sup>1,2,7-15</sup> Misdiagnosis may be responsible for an underestimate of the prevalence of QSS.<sup>16</sup> Cahill<sup>7</sup> described four cardinal features of QSS: (a) poorly localized shoulder pain, (b) nondermatomal distribution of paresthesia, (c) discrete point tenderness in the quadrilateral space, and (d) a positive arteriogram finding with the affected shoulder in a position of abduction and external rotation. A high index of suspicion should be maintained for this unusual diagnosis in the overhead athlete who presents with recalcitrant posterior shoulder pain.

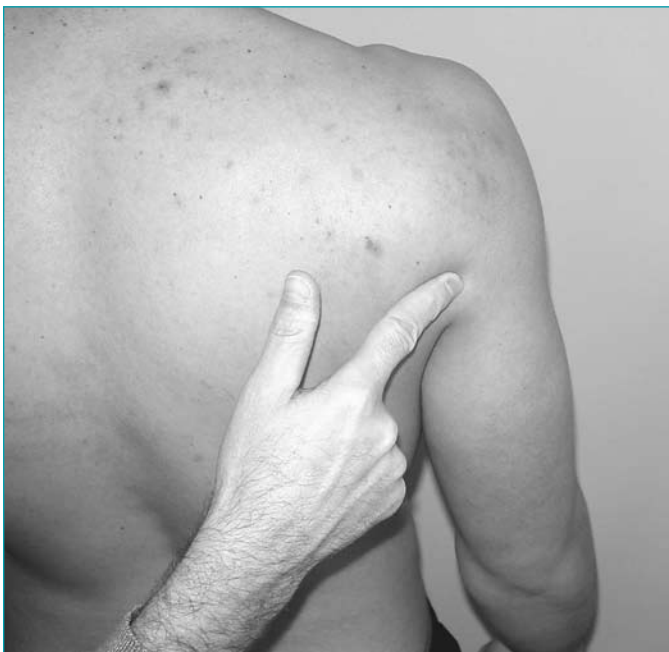## Examination

The athlete who has QSS will typically complain of vague pain in the shoulder and around the shoulder that can radiate as far distally as the forearm in a nondermatomal pattern.<sup>3,16</sup> This may be experienced before, during, and after physical exertion. There is often isolated tenderness in response to palpation over the quadrilateral space, which is very close to the posterior rotator cuff muscles, teres minor, and infraspinatus (Figure 2). McAdams and Dillingham<sup>17</sup> recently reported the opinion that the most important findings in patients with QSS are pain in the quadrilateral space and a positive



**Figure 1** View of quadrilateral space.

Reprinted with permission from Agur ARM. *Grant's Atlas of Anatomy*. 9th ed. Baltimore: Williams and Wilkins; 1991, pg 386.



**Figure 2** View of area of point tenderness in posterior shoulder.

lidocaine block test. Active range of motion for external rotation of the shoulder is typically full, but is painful at the end-range. Manual pressure applied to end-range internal rotation may elicit symptoms.

Neurologic examination is normal in most cases, but atrophy of the deltoid may be present.<sup>16</sup> In chronic cases, the lesion must be distal to the quadrilateral

space when the posterior deltoid and teres minor are not affected.<sup>18</sup>

We have commonly seen a thickened band along the border between the teres minor and infraspinatus muscle tendons in baseball pitchers. Typically, this thickening is attributed to hypertrophic connective tissue of the involved musculature. A number of authors have identified such a hypertrophic band of connective tissue as a potential cause of compression in the quadrilateral space.<sup>7,10,17,19-20</sup> Athletic trainers should consider QSS in the differential diagnosis of posterior shoulder pain. Definitive diagnosis may require an angiogram to identify an occlusion of the circumflex scapular artery, which accompanies the axillary nerve through the quadrilateral space.

### Conservative Management

At least six months of conservative management is recommended before surgical intervention is performed.<sup>3,12,14,16,17,21,23</sup> During this six-month period, treatment should include NSAIDs, therapeutic exercise, manual therapy, and restriction of activities that produce symptoms. Glenohumeral joint mobilization, rotator cuff and scapular strengthening, cross-friction massage, and posterior capsule stretching have been found to provide beneficial effects.

A key rehabilitation goal should be prevention of joint contractures through preservation of the maximum range of motion.<sup>21</sup> Weakness of the deltoid and teres minor is commonly associated with QSS, which can lead to abnormal arthrokinematics of the shoulder complex and secondary conditions (e.g., subacromial impingement). Strengthening of the rotator cuff and scapular stabilizers should begin with isometric exercises and progress to concentric exercises.<sup>14,21</sup>

Hoskins et al.<sup>14</sup> suggested that the posterior capsule should be addressed as part of the cause of a dysfunctional arthrokinematic pattern of motion. A treatment plan to address this consideration may include posterior and inferior glide joint mobilization techniques.<sup>3,14</sup> Stretching into horizontal adduction has also been reported to provide benefit. The findings of a recently reported randomized clinical trial suggest that a combination of posterior capsule stretching and posterior capsule joint mobilization produces better results than stretching alone (Figure 3).<sup>23</sup>

Fibrous bands and adhesions can form along the posterior band of the inferior glenohumeral ligament, which may produce symptoms associated with QSS. Hoskins et al.<sup>14</sup> performed friction massage and soft tissue mobilization to the area the axillary nerve within the quadrilateral space, which they reported to provide great benefit.

If conservative treatment fails to relieve QSS symptoms, the athlete should be referred for further evaluation by his or her physician. Conservative management is not successful for every case of QSS. Surgical release of abnormal connective tissue within the quadrilateral space may be necessary for resolution of the condition. ■



**Figure 3** Posterior capsule joint mobilization technique.

## References

1. Cormier PJ, Matalon TA, Wolin PM. Quadrilateral space syndrome: a rare cause of shoulder pain. *Radiology*. 1988;167:797-798.
2. Redler MR, Ruland LJ, McCue FC. Quadrilateral space syndrome in a throwing athlete. *Am J Sports Med*. 1986;14:511-513.
3. Dugas JR, Weiland AJ. Vascular pathology in the throwing athlete. *Hand Clin*. 2000;16:477-485.
4. Baker CL Jr, Liu SH. Neurovascular injuries to the shoulder. *J Orthop Sports Phys Ther*. 1993;18:360-364.
5. Linker CS, Helms CA, Firtz RC. Quadrilateral space syndrome: Findings at MR imaging. *Radiology*. 1993;188:675-676.
6. Liveson J. Nerve lesions associated with shoulder dislocation: an electrodiagnostic study of 11 cases. *J Neurol Neurosurg Psychiatry*. 1984;47:742-744.
7. Cahill BR, Palmer RE. Quadrilateral space syndrome. *J Hand Surg*. 1983;8:65-69.
8. Aita JF. An unusual compressive neuropathy. *Arch Neurol*. 1984;41:341.
9. Nuber GW, McCarthy WJ, Yao JST, et al. Arterial abnormalities of the shoulder in athletes. *Am J Sports Med*. 1990;18:514-519.
10. Fracel TJ, Dellon AL, Campbell JN. Quadrilateral space syndrome: diagnosis and operative decompression technique. *Plast Reconstr Surg*. 1991;87:911-916.
11. Reekers JA, Den Hartog BM, Kuyper CR, et al. Traumatic aneurysm of the posterior circumflex artery: a volleyball player's disease? *J Vasc Interv Radiol*. 1993;4:405-408.
12. Okino S, Miyaji H, Matoba M. The quadrilateral space syndrome. *Neuroradiology*. 1995;37:311-312.
13. Chen D, Cai P, Lao G, et al. Quadrilateral space syndrome. *Chin Med J*. 1995;108:109-112.
14. Hoskins WT, Pollard HP, McDonald AJ. Quadrilateral space syndrome: a case study and review of the literature. *Br J Sports Med*. 2005;39:e9.
15. Paladini D, Dellantonio R, Cinti A, et al. Axillary neuropathy in volleyball players: Report of two cases and literature review. *J Neurosurg Psychiatry*. 1996;60:345-347.
16. Chautems RC, Glauser T, Waeber-Fey MC, Rostan O, Barraud GE. Quadrilateral space syndrome: case report and review of the literature. *Ann Vasc Surg*. 2000;14:673-676.
17. McAdams TR, Dillingham MF. Surgical decompression of the quadrilateral space in overhead athletes. *Am J Sports Med*. 2008;36:528-532.
18. Steinmann SP, Moran EA. Axillary nerve injury: Diagnosis and treatment. *J Am Acad Orthop Surg*. 2001;9:328-335.
19. McKowen HC, Voorhies RM. Axillary nerve entrapment in the quadrilateral space: a case report. *J Neurosurg*. 1987;66:932-934.
20. McClelland D, Paxinos A. The anatomy of the quadrilateral space with reference to quadrilateral space syndrome. *J Shoulder Elbow Surg*. 2008;17:162-164.
21. Perlmutter GS. Axillary nerve injury. *Clin Orthop*. 1999;368:28-36.
22. Lester B, Jeong GK, Weiland AJ, et al. Quadrilateral space syndrome: diagnosis, pathology, and treatment. *Am J Orthop*. 1999;28:718-22, 725.
23. Manske RC, Meschke M, Porter A, Smith BS, Reiman M. A randomized, controlled, single-blind comparison of stretching versus stretching and joint mobilization for posterior shoulder tightness. *Sports Health: A Multidisciplinary Approach*. 2008. In review.

**Robert C. Manske** is an associate professor at Wichita State University Department of Physical Therapy.

**Afton Sumler** is with the Wichita State University Department of Physical Therapy.

**Jodi Runge** is with the Wichita State Department of Physical Therapy.